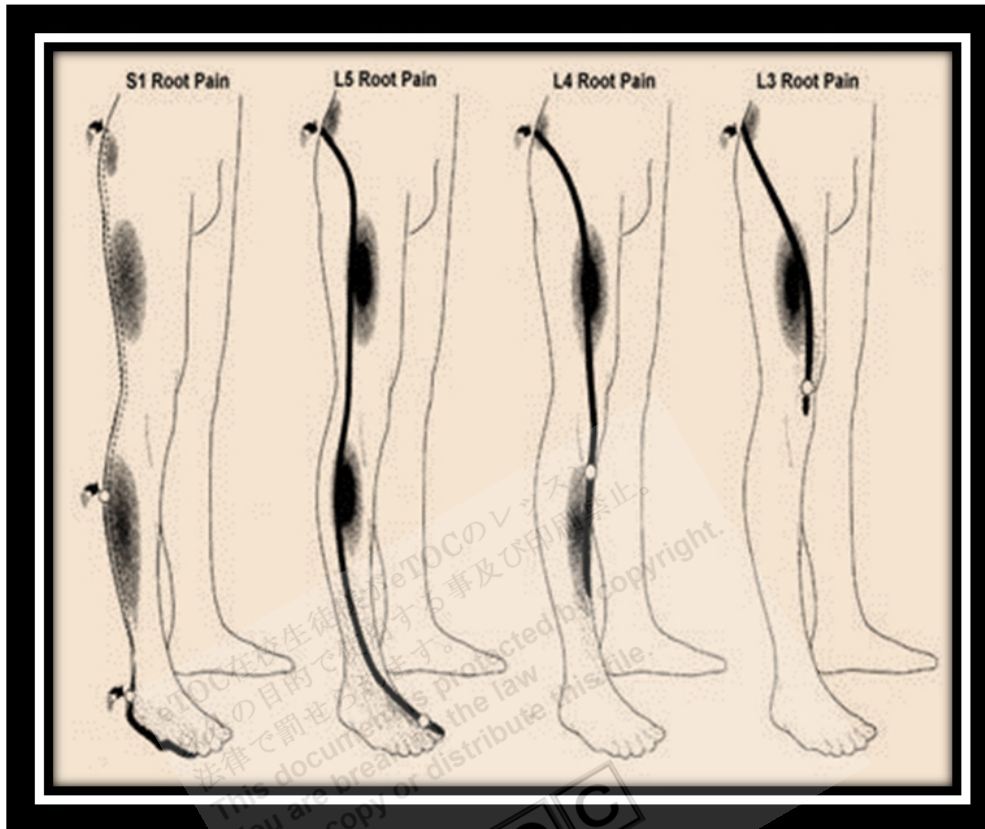

Limb Pain



<http://www.spinesurgeons.ac.uk/data/images/S1L5L4L3PAIN.jpg>

Limb pain may affect all or part of an extremity. Pain may be constant or **intermittent**, and unrelated to motion or precipitated by it. Accompanying symptoms and signs often suggest a source.

Etiology

Musculoskeletal injuries and overuse are the most common causes of pain in a limb but are readily apparent by history. This discussion covers extra-articular limb pain unrelated to injury or strain. Pain that is in only one or more joints is discussed elsewhere. There are many causes but the most common are the following:

- Deep venous thrombosis (DVT)
- **Cellulitis**
- **Radiculopathy**

Uncommon but serious causes that require immediate diagnosis and treatment include

- **Acute arterial occlusion**
- Deep soft tissue infection
- **Acute coronary ischemia** (manifesting with only referred arm pain)

Table 9

Some Causes of Nontraumatic Limb Pain		
Cause	Suggestive Findings	Diagnostic Approach
Musculoskeletal and soft tissue		
Cellulitis	Focal redness, warmth, tenderness, swelling Sometimes fever	Clinical evaluation Sometimes blood and tissue cultures (eg, when patients are immunocompromised)
Deep soft-tissue infection (eg, myonecrosis, necrotizing subcutaneous infection)	Deep, constant pain, typically out of proportion to other findings Redness, warmth, tenderness, tense swelling, fever Sometimes crepitation , foul discharge, bullae or necrotic areas , signs of systemic toxicity (eg, delirium, tachycardia, pallor, shock)	Blood and tissue cultures X-ray Sometimes MRI
Osteomyelitis	Deep, constant, often nocturnal pain Bone tenderness, fever Often risk factors (eg,	X-ray, MRI, and/or CT Sometimes bone culture

immunocompromise,
parenteral drug use,
known contiguous or
remote source for
infection)

Bone tumor
(primary or
metastatic)

Deep, constant, often
nocturnal pain
Bone tenderness
Often a known
cancer

X-ray, MRI, and/or CT

Vascular

Deep venous
thrombosis

Swelling, often
warmth and/or
redness, sometimes
venous distension
Often risk factors (eg,
hypercoagulable
state, recent surgery
or immobility,
cancer)

Ultrasonography
Possibly D-dimer testing

Chronic venous
stasis

Mild discomfort with
swelling, erythema,
and warmth of distal
lower extremity
Sometimes shallow
ulcerations

Clinical evaluation

Acute ischemia
(typically due
to arterial
embolism or
thrombosis but
sometimes due
to massive

Sudden, severe pain
Signs of distal limb
ischemia (eg,
coolness, pallor,
pulse deficits,
delayed capillary
refill)

Immediate **arteriography**

iliofemoral venous thrombosis that completely obstructs flow in the limb)

Sometimes chronic ischemic skin changes (eg, atrophy, hair loss, pale color, ulceration)

After several hours, neurologic deficits and muscle tenderness

Sometimes known peripheral vascular disease

Peripheral arterial insufficiency

Intermittent leg pain triggered predictably by exertion and relieved by rest (**intermittent claudication**), sometimes rest pain which may worsen with leg elevation

Low ankle-brachial BP index, chronic ischemic skin changes

Ultrasonography
Sometimes **arteriography**

Neurologic

Plexopathy (**brachial** or **lumbar**)

Pain; usually weakness, decreased reflexes

Sometimes numbness in a nerve **plexus** distribution

Usually **electrodiagnostic** testing (**electromyography** and nerve conduction velocity)

Sometimes MRI

Thoracic outlet

Pain and **paresthesias**

Unclear, but possibly

syndrome	beginning in neck or shoulder and extending to medial aspect of arm and hand	electrodiagnostic testing and/or MRI
Radiculopathy (eg, caused by herniated intervertebral disk or bone spurs)	Pain and sometimes sensory deficits following a dermatomal distribution and often worsening with movement Often neck or back pain Usually weakness and diminished deep tendon reflexes in a nerve root distribution	Usually MRI
Painful polyneuropathy (eg, alcoholic neuropathy)	Chronic, burning pain, typically in both hands or both feet Sometimes sensory abnormalities such as hypoesthesia, hyperesthesia , and/or allodynia (pain with non-noxious stimuli)	Clinical evaluation
Complex regional pain syndrome (CRPS)	Burning pain, hyperesthesia, allodynia, vasomotor abnormalities Typically a prior injury	Clinical evaluation

(may be remote)

Other

Acute coronary ischemia (causing referred arm pain)	Absence of explanatory physical findings at the site of pain; other suggestive findings (eg, history suggesting coronary artery disease, sweating and/or dyspnea occurring simultaneously with arm pain)	ECG and serum troponin Sometimes stress testing or coronary angiography
---	--	--

Myofascial pain syndrome

Chronic pain and tenderness along a taut band of muscle, worsening with movement and with pressure on a trigger point (focal area separate from site of pain)	Clinical evaluation
---	---------------------

Evaluation

It is important to exclude **acute arterial occlusion**.

History: History of present illness should address the duration, intensity, location, quality, and temporal pattern of pain. Recent injury, excessive and/or unusual use, and factors that worsen pain (eg, limb movement, walking) and relieve pain (eg, rest, certain positions) should be noted. Any associated neurologic symptoms (eg, numbness, **paresthesias**) should be identified.

Review of systems should seek symptoms of possible causes, including back or neck pain (**radiculopathy**), fever (infections such as **osteomyelitis**, cellulitis, or deep soft tissue infection), dyspnea (DVT with pulmonary embolism, MI), and chest pain or sweating (cardiac ischemia).

Past medical history should identify known risk factors, including cancer (metastatic bone tumors); immunocompromising disorders or drugs (infections); hypercoagulable states (DVT); diabetes (peripheral vascular disease with limb ischemia); peripheral vascular disease, **hypercholesterolemia**, and/or hypertension (acute or chronic ischemia); **osteoarthritis** or RA (radiculopathy); and prior injury (complex regional pain syndrome [CRPS]). Family and social history should address family history of early vascular disease and cigarette smoking (limb or cardiac ischemia) and illicit use of parenteral drugs (infections).

Physical examination: Vital signs are reviewed for fever (suggesting infection) and tachycardia and/or tachypnea (compatible with DVT with pulmonary embolism, MI, and infection with sepsis).

The painful limb is inspected for color, edema, and any skin or hair changes, and palpated for pulses, temperature, tenderness, and **crepitation** (a subtle crackling sensation indicating soft tissue gas). Strength, sensation and deep tendon reflexes are compared between affected and unaffected sides. Systolic BP is measured in the ankle of the affected extremity and compared with systolic BP of an arm; the ratio of the two is the **ankle-brachial index**.


- Sudden, severe pain
- Signs of acute limb ischemia (eg, coolness, pallor, pulse deficits, delayed capillary refill)
- Dyspnea, chest pain, and/or sweating
- Signs of systemic toxicity (eg, delirium, tachycardia, shock, pallor)
- Crepitation, tenseness, foul discharge, bullae, necrosis
- Risk factors for deep venous thrombosis
- Neurologic deficits

Interpretation of findings: It can be helpful to categorize patients by acuity of symptoms and then further narrow the differential diagnosis based on presence or absence of findings of

- Ischemia
- Inflammation
- Neurologic abnormalities

Sudden, severe pain suggests acute ischemia or acute radiculopathy (eg, from sudden disc **herniation**). Acute ischemia causes generalized limb pain and

manifests with weak or absent pulse, delayed capillary refill, coolness, and pallor; ankle-brachial index is typically < 0.3 . Such vascular signs are absent with radiculopathy, in which pain instead follows a dermatomal distribution and is often accompanied by back or neck pain and diminished deep tendon reflexes. However, in both cases, weakness may be present. Acute ischemia due to massive venous thrombosis (**phlegmasia cerulea dolens**) usually causes edema, which is not present in ischemia due to arterial occlusion.



<http://www.neuroanatomy.wisc.edu/SClinic/Radiculo/gradicup.jpg>

In **subacute pain** (ie, of 1 to a few days' duration), redness and tenderness, often accompanied by swelling, and/or warmth, suggest an inflammatory cause. If these findings are focal or circumscribed, cellulitis is likely. Generalized, **circumferential swelling** is more suggestive of DVT or, much less commonly, deep tissue infection. Patients with a deep tissue infection typically appear quite ill and may have **blisters**, **necrosis**, or **crepitation**. Findings in DVT vary widely; swelling and warmth may be minimal or absent. Neurologic findings of weakness, paresthesias, and/or sensory abnormalities suggest radiculopathy or **plexopathy**. If neurologic findings follow a dermatomal pattern, radiculopathy is more likely.

Chronic pain can be difficult to diagnose. If neurologic findings are present, causes include radiculopathy (dermatomal distribution), plexopathy (plexus distribution), neuropathy (stocking-glove distribution), and CRPS (variable distribution). CRPS should be suspected if vasomotor changes (eg, pallor, mottling, coolness) are present, particularly in those with previous injury to the affected extremity. **Myofascial pain syndrome** causes no neurovascular abnormalities and classically manifests with a palpably tense band of muscle in the area of pain, and pain may be reproduced by pressure on a trigger point near but not overlying the area of pain. In those with essentially no clinical findings, cancer and osteomyelitis should be considered, particularly in those with risk factors.

Intermittent pain occurring consistently with a given degree of exertion (eg, whenever walking > 3 blocks) and relieved with a few minutes of rest suggests peripheral arterial disease. Such patients typically have an ankle-brachial BP index of ≤ 0.9 ; an index ≤ 0.4 indicates severe disease. Those with peripheral arterial disease may have chronic skin changes (eg, atrophy, hair loss, pale color, ulceration).

Testing: Cellulitis, myofascial pain, **painful polyneuropathy**, and CRPS can often be diagnosed clinically. Testing is usually necessary for other suspected causes of pain.

Treatment

Primary treatment is directed at the cause. Analgesics can help relieve pain.

Key Points

- Acute limb ischemia should be considered in patients with sudden, severe pain.
- Presence or absence of findings of ischemia, inflammation, and neurologic abnormalities plus the **acuity** of onset help narrow the **differential diagnosis**.

Reference: <http://www.merckmanuals.com>