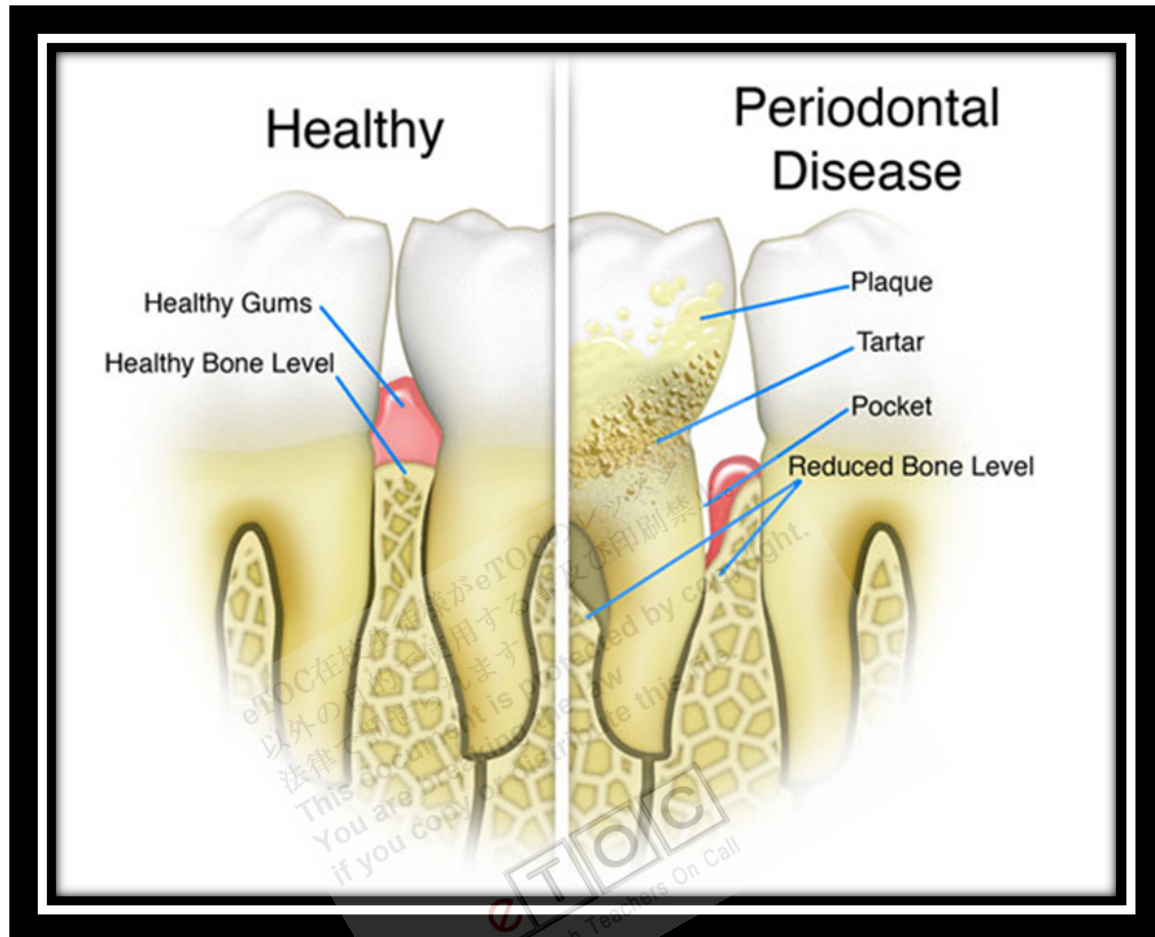


Periodontal Disorders



<http://stevenleedds.com/images/periodontal-disease.jpg>

Periodontitis (pyorrhea) is a chronic inflammatory disease of the gums resulting from an opportunistic infection of endogenous plaque biofilm. It usually manifests as a worsening of gingivitis and then, if untreated, with loosening and loss of teeth. Other symptoms are rare except in patients with HIV infection or in whom abscesses develop, in which case pain and swelling are common. Diagnosis is based on inspection, periodontal probing, and x-rays. Treatment involves dental cleaning that extends under the gums and a vigorous home hygiene program. Advanced cases may require antibiotics and surgery.

Etiology

Periodontitis usually develops when gingivitis, usually with abundant plaque and calculus beneath the gingival margin, has not been adequately treated.

In periodontitis, the deep pockets can harbor anaerobic organisms that do more damage than those usually present in simple gingivitis. The organisms trigger chronic release of inflammatory mediators, including **cytokines**, **prostaglandins**, and **enzymes** from **neutrophils** and **monocytes**. The resulting inflammation affects the periodontal **ligament**, **gingiva**, **cementum**, and **alveolar bone**. The gingiva progressively loses its attachment to the teeth, bone loss begins, and **periodontal pockets** deepen. With progressive bone loss, teeth may loosen, and gingiva recedes. Tooth migration is common in later stages. Tooth loss typically starts in a patient's 40s. A seemingly different kind of periodontitis can begin in the preadolescent years and causes rapid loss of bone and teeth.

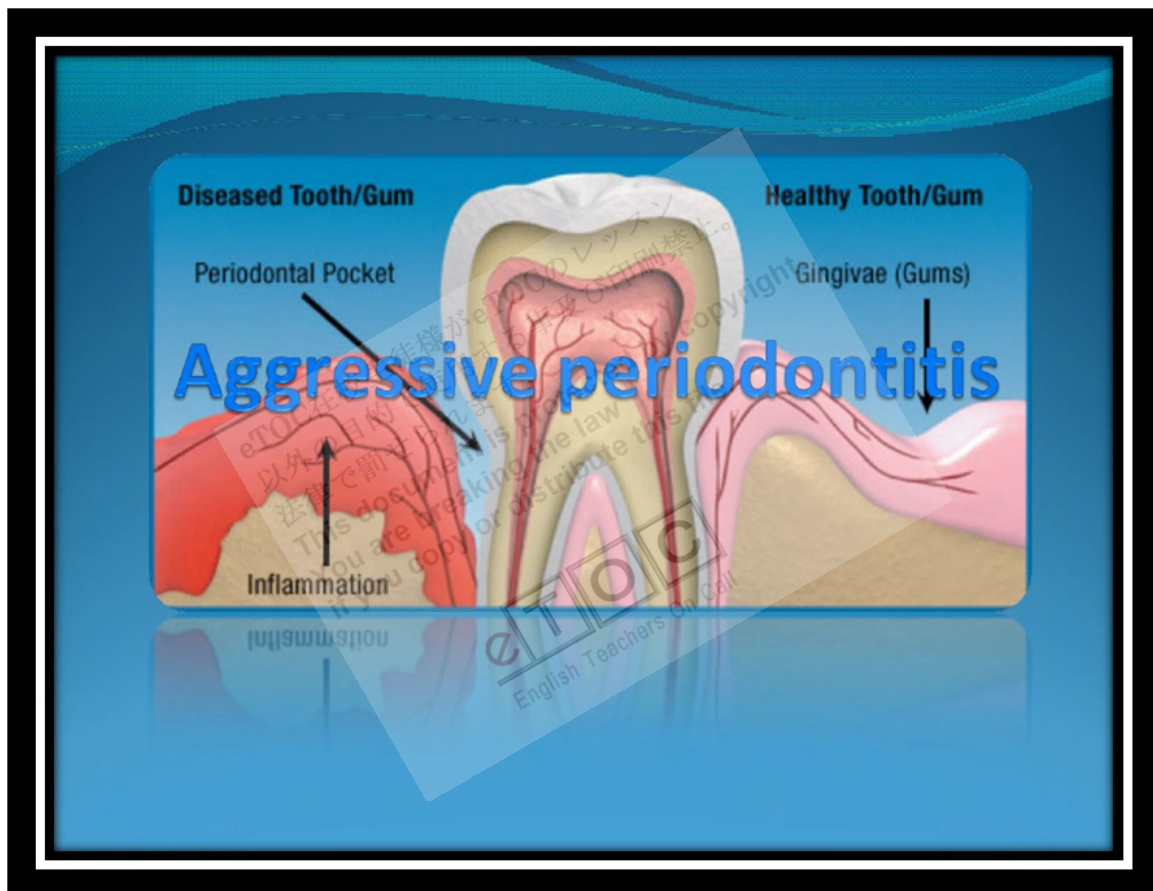Systemic causes: Systemic diseases that predispose patients to periodontitis include diabetes (especially type 1); acquired, familial, and cyclic neutropenia; leukemia; Down syndrome; leukocyte adhesion deficiency syndromes; **Papillon-Lefèvre syndrome**; **Crohn's disease**; **histiocytosis** syndromes; **agranulocytosis**; lazy leukocyte syndrome; **hypogammaglobulinemia**; **Chédiak-Higashi syndrome**; **glycogen storage disease**; **infantile genetic agranulocytosis**; **Ehlers-Danlos syndrome** (types IV and VIII); vitamin C deficiency (**scurvy**); and **hypophosphatasia**. Faulty occlusion, causing an excessive functional load on teeth, plus the requisite plaque and gingivitis may contribute to progression of a particular type of **periodontitis** characterized by angular bony defects.

Pathophysiology

Periodontitis is usually chronic and characterized by periods of **exacerbation** and remission. Chronic **periodontitis** (formerly adult periodontitis) occurs in localized and generalized forms, and people with significant disease tend to be > 35 yr. About 85% of the population is affected to a mild degree, but the most advanced cases are seen in < 5% of the population.

Aggressive periodontitis: Several more rapidly progressive subtypes of chronic periodontitis exist, collectively known as aggressive periodontitis. Aggressive periodontitis may develop as early as childhood, sometimes before age 3 yr. Patients may have severe bone loss, even tooth loss, by age 20. **Neutrophil** function may be defective in aggressive periodontitis; its clinical significance is unknown.

In one type of aggressive periodontitis that occurs in healthy adolescents (formerly called localized **juvenile periodontitis**), patients often have significant colonization of *Aggregatibacter actinomycetemcomitans* (formerly *Actinobacillus actinomycetemcomitans*). Typically, the signs of inflammation are minor. The disease is detected by periodontal probing or x-rays, which show localized, deep (vertical) bone loss, commonly limited to the 1st molars and incisors. Bone loss progresses faster than in adult periodontitis, often at a rate of 3 to 4µm/day.



http://4.bp.blogspot.com/_nG0qhELTpFM/TQdjzKqONUI/AAAAAAAAATE/Kg5t1ROfz_8/s1600/000.jpg

An uncommon type of aggressive periodontitis (formerly called prepubertal periodontitis) affects deciduous teeth, usually shortly after eruption. Generalized acute proliferative gingivitis and rapid alveolar bone destruction are its hallmarks. Patients also have frequent bouts of otitis media and are usually diagnosed by age 4 yr. In some patients, the disease resolves before the permanent teeth erupt.

Prototypical aggressive periodontitis (formerly called rapidly progressive periodontitis) occurs in patients aged 20 to 35. It is often associated with *A. actinomycetemcomitans*, *Porphyromonas gingivalis*, *Eikenella corrodens*, and many gram-negative bacilli, but cause and effect are not clear. Some cases result from undiagnosed localized juvenile periodontitis or prepubertal periodontitis, but others appear independently.

HIV-associated periodontitis is a particularly virulent, rapidly progressing disease. Clinically, it resembles acute necrotizing ulcerative gingivitis combined with rapidly progressive periodontitis. Patients may lose 9 to 12 mm of attachment in as little as 6 mo.

Symptoms and Signs

Pain is usually absent unless an acute infection forms in one or more **periodontal pockets** or if HIV-associated periodontitis is present. Impaction of food in the pockets can cause pain at meals. Abundant plaque along with redness, swelling, and exudate are characteristic. Gums may be tender and bleed easily, and breath may be foul. As teeth loosen, particularly when only one third of the root is in the bone, chewing becomes painful.

Diagnosis

- Clinical evaluation
- Sometimes dental x-rays

Inspection of the teeth and gingiva combined with probing of the pockets and measurement of their depth are usually sufficient for diagnosis. Pockets deeper than 4 mm indicate periodontitis. Dental x-rays reveal alveolar bone loss adjacent to the periodontal pockets.

Treatment

- Scaling and root planing
- Sometimes oral antibiotics, antibiotic packs, or both
- Surgery or extraction

For all forms of periodontitis, the first phase of treatment consists of thorough scaling (professional cleaning with hand or ultrasonic instruments) and root planing (removal of diseased or toxin-affected **cementum** and dentin followed by smoothing of the root) to remove plaque and calculus deposits. Thorough home oral hygiene is necessary. The patient is reevaluated after 3 wk. If pockets are no deeper than 4 mm at this point,

the only treatment needed is regular cleanings. Sometimes a flap of gum tissue is made to allow access for scaling and planing of deeper parts of the root.

If deeper pockets persist, systemic antibiotics can be used. A common regimen is **isamoxicillin** 500 mg po tid for 10 days. In addition, a gel containing doxycycline or **microspheres of minocycline** can be placed into **isolated recalcitrant pockets**. These drugs are resorbed in 2 wk.

Another approach is to surgically eliminate the pocket and **recontour** the bone (pocket reduction/elimination surgery) so that the patient can clean the depth of the normal crevice (sulcus) between the tooth and gingiva. In certain patients, regenerative surgery and bone grafting are done to encourage **alveolar bone** growth. Splinting of loose teeth and selective reshaping of tooth surfaces to eliminate traumatic occlusion may be necessary. Extractions are often necessary in advanced disease. Contributing systemic factors should be controlled before initiating periodontal therapy.

Ninety percent of patients with HIV-associated periodontitis respond to combined treatment with scaling and planing, irrigation of the sulcus with **povidone-iodine** (which the dentist applies with a syringe), regular use of **chlorhexidine** mouth rinses, and systemic antibiotics, **usually metronidazole** 250 mg po tid for 14 days.

Localized juvenile periodontitis requires periodontal surgery plus oral antibiotics (eg, amoxicillin 500 mg qid or **metronidazole** 250 mg tid for 14 days).

Key Points

- Periodontitis is an inflammatory reaction triggered by bacteria in dental plaque.
- There is loss of alveolar bone, formation of deep gum pockets, and eventually loosening of teeth.
- Treatment involves scaling and root planing and sometimes antibiotics and/or surgery.

Reference: <http://www.merckmanuals.com>