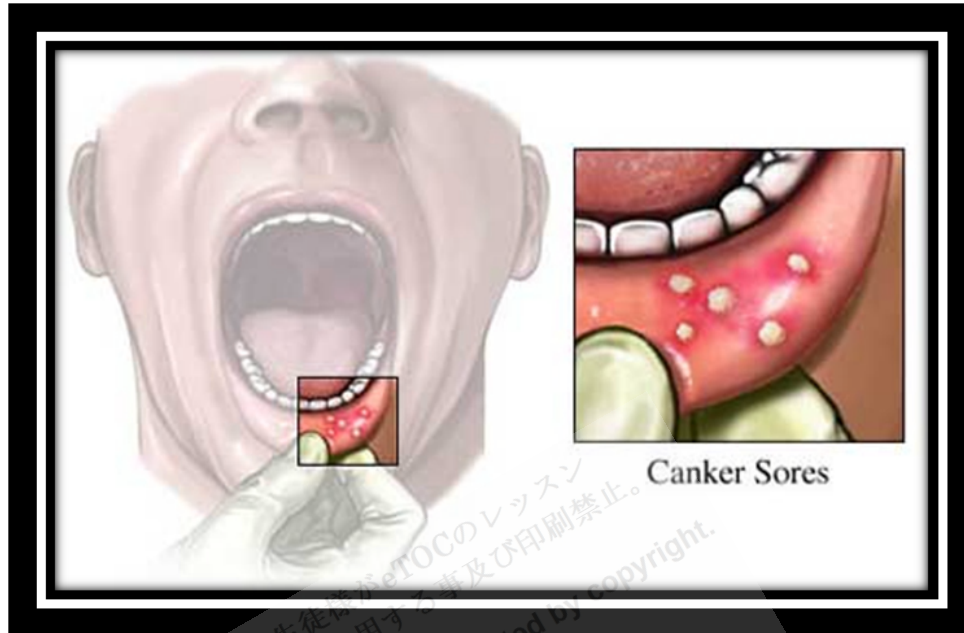


Recurrent Aphthous Stomatitis



<http://www.intelligentdental.com/wp-content/uploads/2012/04/canker-sores2.jpg>

Recurrent aphthous stomatitis is a common condition in which round or ovoid painful ulcers recur on the oral mucosa. Etiology is unclear. Diagnosis is clinical. Treatment is symptomatic and usually includes topical corticosteroids.

Recurrent aphthous stomatitis (RAS) affects 20 to 30% of adults and a greater percentage of children at some time in their life.

Etiology

Etiology is unclear, but RAS tends to run in families. The damage is predominately cell-mediated. Cytokines, such as IL-2, IL-10, and, particularly, tumor necrosis factor- α , play a role.

Predisposing factors include

- Oral trauma
- Stress
- Foods, particularly chocolate, coffee, peanuts, eggs, cereals, almonds, strawberries, cheese, and tomatoes

Allergy does not seem to be involved.

Factors that may, for unknown reasons, be *protective* include oral contraceptives, pregnancy, and tobacco, including smokeless tobacco and nicotine-containing tablets.

Symptoms and Signs

Symptoms and signs usually begin in childhood (80% of patients are < 30 yr) and decrease in frequency and severity with aging. Symptoms may involve as few as one ulcer 2 to 4 times/yr or almost continuous disease, with new ulcers forming as old ones heal. A **prodrome** of pain or burning for 1 to 2 days precedes ulcers, but there are no antecedent vesicles or bullae. Severe pain, disproportionate to the size of the lesion, can last from 4 to 7 days.

Ulcers are well-**demarcated**, shallow, ovoid, or round and have a necrotic center with a yellow-gray **pseudomembrane**, a red halo, and slightly raised red margins.

Minor aphthae (**Mikulicz's disease**) account for 85% of cases. They occur on the floor of the mouth, lateral and ventral tongue, **buccal mucosa**, and pharynx; are < 8 mm (typically 2 to 3 mm); and heal in 10 days without scarring.

Major aphthae (**Sutton's disease**, **peradenitis mucosa necrotica recurrens**) constitute 10% of cases. Appearing after puberty, the **prodrome** is more intense and the ulcers are deeper, larger (> 1 cm), and longer lasting (weeks to months) than minor **aphthae**. They appear on the lips, soft palate, and throat. Fever, **dysphagia**, **malaise**, and scarring may occur.

Herpetiform ulcers (morphologically resembling but unrelated to herpes virus) account for 5% of cases. They begin as multiple (up to 100) 1- to 3-mm crops of small, painful clusters of ulcers on an **erythematous** base. They **coalesce** to form larger ulcers that last 2 wk. They tend to occur in women and at a later age of onset than do other forms of RAS.

Diagnosis

- Clinical evaluation

Evaluation proceeds as described previously under stomatitis. Diagnosis is based on appearance and on exclusion, because there are no definitive histologic features or laboratory tests.

Primary oral **herpes simplex** may mimic RAS but usually occurs in younger children, always involves the gingiva and may affect any keratinized mucosa (**hard palate, attached gingiva, dorsum of tongue**), and is associated with systemic symptoms. Viral culture can be done to identify herpes simplex. Recurrent herpetic lesions are usually unilateral.

Similar recurrent episodes can occur with **Behçet's syndrome**, inflammatory bowel disease, sprue, HIV infection, and nutritional deficiencies; these conditions generally have systemic symptoms and signs. Isolated recurrent oral ulcers can occur with herpes infection, HIV, and, rarely, nutritional deficiency. Viral testing and serum hematologic tests can identify these conditions.

Drug reactions may mimic RAS but are usually temporally related to ingestion. However, reactions to foods or dental products may be difficult to identify; sequential elimination may be necessary.

Treatment

- Topical **chlorhexidine** and **corticosteroids**

General treatments for stomatitis may help patients with RAS. **Chlorhexidine gluconate** mouthwashes and topical corticosteroids, the mainstays of therapy, should be used during the **prodrome**, if possible. The **corticosteroid** can be **dexamethasone** 0.5 mg/5 mL tid used as a rinse and then expectorated **orclobetasol** ointment 0.05% or **fluocinonide** ointment 0.05% in **carboxymethylcellulose** mucosal protective paste (1:1) applied tid. Patients using these **corticosteroids** should be monitored for **candidiasis**. If topical corticosteroids are ineffective, prednisone (eg, 40 mg po once/day) may be needed for ≤ 5 days. Continuous or particularly severe RAS is best treated by a specialist in oral medicine. Treatment may require prolonged use of systemic **corticosteroids**, azathioprine or other **immunosuppressants**, **pentoxifylline**, **orthalidomide**. **Intralesional** injections can be done with **betamethasone**, **dexamethasone**, or **triamcinolone**. Supplemental B₁, B₂, B₆, B₁₂, folate, or iron lessens RAS in some patients.

Reference: <http://www.merckmanuals.com>