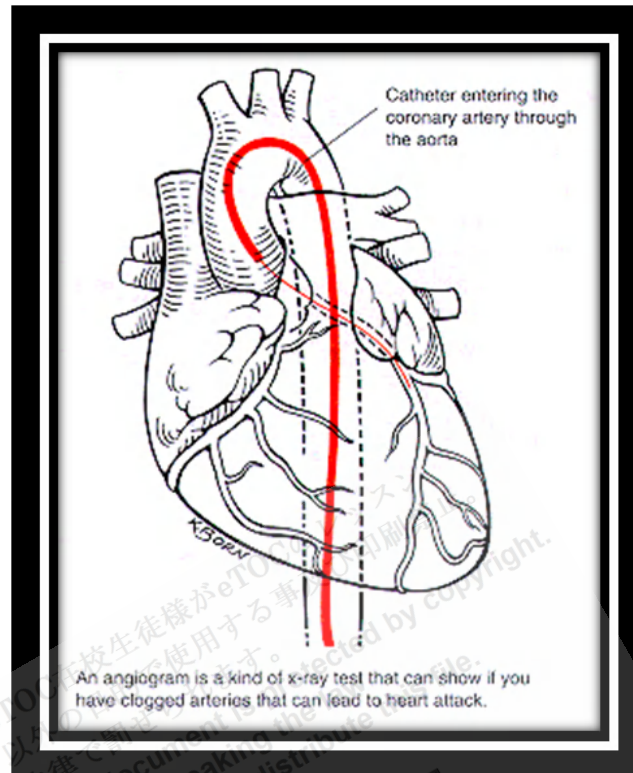


Cardiac Catheterization



<http://www.rochestermedicalcenter.com/images/carca.gif>

Cardiac catheterization is the passage of a catheter through peripheral arteries or veins into cardiac chambers, the pulmonary artery, and coronary arteries and veins. Cardiac catheterization can be used to do various tests, including angiography, intravascular ultrasonography, measurement of cardiac output (CO), detection and quantification of shunts, endomyocardial biopsy, and measurements of myocardial metabolism. These tests define coronary artery anatomy, cardiac anatomy, and cardiac function to establish diagnoses and help select treatment. Cardiac catheterization is also the basis for several therapeutic interventions.

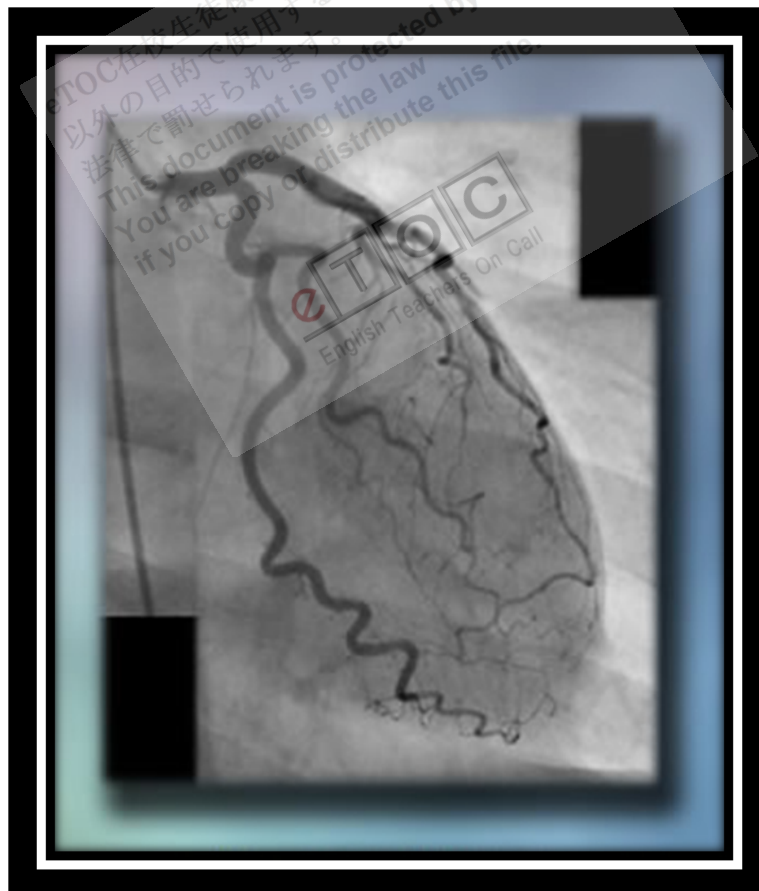Procedure

Patients must be NPO for 4 to 6 h before cardiac catheterization. Most patients do not require overnight hospitalization.

Left heart catheterization is most commonly used to assess coronary artery anatomy; it is also useful for assessing aortic BP and systemic vascular resistance, aortic and mitral valve function, and left ventricular (LV) pressure and function. The procedure is done by percutaneous femoral, radial, or brachial artery puncture, with a catheter

passed into the coronary artery ostia or across the aortic valve into the LV. Catheterization of the left atrium (LA) and LV is occasionally done using transseptal perforation during right heart catheterization.

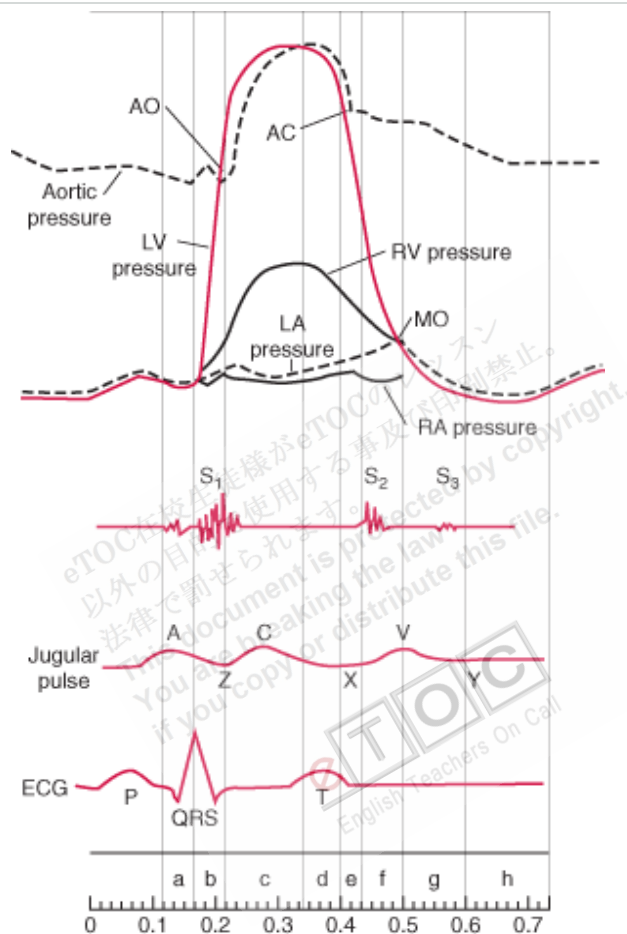
Right heart catheterization is most commonly used to assess right atrial (RA), right ventricular (RV), and pulmonary artery pressure and pulmonary artery occlusion pressure PAOP approximates LA and LV end-diastolic pressure. In seriously ill patients, PAOP helps assess volume status and, with simultaneous measurements of CO, can help guide therapy. Right heart catheterization is also useful for assessing pulmonary vascular resistance, tricuspid or pulmonic valve function, intracardiac shunts, and RV pressure. Right heart pressure measurements may help in the diagnosis of cardiomyopathy, **constrictive pericarditis**, and **cardiac tamponade** when noninvasive testing is nondiagnostic. The procedure is done by **femoral**, **subclavian**, **internal jugular**, or **antecubital vein puncture**. A catheter is passed into the RA, through the **tricuspid valve**, into the RV, and across the pulmonary valve into the pulmonary artery. Selective catheterization of the coronary sinus can also be done.



<http://www.mymethodist.net/img/mmc/cath/cath.jpg>

Fig. 1

Diagram of the cardiac cycle, showing pressure curves of the cardiac chambers, heart sounds, jugular pulse wave, and the ECG.



The phases of the cardiac cycle are atrial systole (a), isometric contraction (b), maximal ejection (c), reduced ejection (d), protodiastolic phase (e), isometric relaxation (f), rapid inflow (g), and diastasis, or slow LV filling (h). For illustrative purposes, time intervals between valvular events have been modified, and the z point has been prolonged.

AO = aortic valve opening; AC = aortic valve closing; LV = left ventricle; LA = left atrium; RV = right ventricle; RA = right atrium; MO = mitral valve opening.

Specific Tests During Cardiac Catheterization

Angiography: Injection of **radiopaque dye** into coronary or pulmonary arteries, the aorta, and cardiac chambers is useful in certain circumstances. Digital subtraction angiography is used for nonmoving arteries and for chamber **cineangiography**.

Coronary angiography via left heart catheterization is used to evaluate coronary artery anatomy in various clinical situations, as in patients with suspected coronary atherosclerotic or congenital disease, valvular disorders before valvular replacement, or unexplained heart failure.

Pulmonary angiography via right heart catheterization is used to diagnose pulmonary embolism. **Intraluminal filling defects** or arterial cutoffs are diagnostic. Radiopaque dye is usually selectively injected into one or both pulmonary arteries and their segments. Computed tomographic pulmonary angiography (CTPA) has largely replaced right heart catheterization for diagnosis of pulmonary embolism.

Aortic angiography via left heart catheterization is used to assess aortic regurgitation, coarctation, **patent ductus arteriosus**, and dissection.

Ventriculography is used to visualize ventricular wall motion and ventricular outflow tracts, including subvalvular, valvular, and supra-valvular regions. It is also used to estimate severity of mitral valve regurgitation and determine its pathophysiology. After LV mass and volume are determined from single planar or biplanar ventricular angiograms, end-systolic and end-diastolic volumes and ejection fraction can be calculated.

Intravascular ultrasonography: Miniature ultrasound transducers on the end of coronary artery catheters can produce images of coronary vessel lumina and walls and delineate blood flow. This technique is being increasingly used at the same time as coronary angiography.

Tests for cardiac shunts: Measuring blood O₂ content at successive levels in the heart and great vessels can help determine the presence, direction, and volume of central shunts. The maximal normal difference in O₂ content is 0.5 mL/dL between the pulmonary artery and RV, 0.9 mL/dL between the RV and RA, and 1.9 mL/dL between the RA and superior vena cava. If the blood O₂ content in a chamber exceeds that of the more **proximal chamber** by more than these values, a left-to-right shunt at that level is probable. Right-to-left shunts are strongly suspected when LA, LV, or arterial O₂ saturation is low ($\leq 92\%$) and does not improve when pure O₂ (fractional inspirational

O₂ = 1.0) is given. Left heart or arterial **desaturation** plus increased O₂ content in blood samples drawn beyond the shunt site on the right side of circulation suggests a bidirectional shunt.

Measurement of cardiac output and flow: CO is the volume of blood ejected by the heart per minute (normal at rest: 4 to 8 L/min). Techniques used to calculate CO include the Fick, indicator-dilution, and thermodilution techniques.

Table 2

Cardiac Output Equations

Fick technique

$$CO = \frac{\text{Ambient } O_2 - \text{Expired } O_2 \text{ (mL/min)}}{(1.36) (\text{Hb g/dL}) \times (\text{SaO}_2 - \text{SvO}_2)}$$

Numerator is O₂ absorbed by lungs (mL/min).

Indicator-dilution technique

$$CO = \frac{\text{Injectate mass (mg)}}{\int_{\infty} C(t) dt}$$

Denominator is the sum of dye concentrations (C) at each time interval (t).

Thermodilution technique

$$CO = \frac{(T_B - T_I) \times \text{injectate volume (mL)} \times 53.5}{\int_{\infty} T_B(t) dt}$$

T_B – T_I is the difference between body and **injectate** temperatures; injectate is usually dextrose or saline.

Denominator is the sum of changes in temperature at each time interval (t).

SaO₂ = arterial O₂ saturation (%); SvO₂ = mixed venous O₂ saturation (%), measured in the pulmonary artery.

With the Fick technique, CO is proportional to O₂ consumption divided by arteriovenous O₂ difference.

Dilution techniques rely on the assumption that after an indicator is injected into the circulation, it appears and disappears proportionately to CO.

Usually, CO is expressed in relation to BSA as the cardiac index (CI) in L/min/m² (ie, CI= CO/BSA. BSA is calculated using DuBois height (ht)-weight (wt) equation:

$$BSA \text{ in } m^2 = (wt \text{ in } kg)^{0.425} \times (ht \text{ in } cm)^{0.725} \times 0.007184$$

Table 3

Normal Values for Cardiac Index and Related Measurements

Measurement	Normal Value	SD
O ₂ uptake	143 mL/min/m ² *	14.3
Arteriovenous O ₂ difference	4.1 dL	0.6
Cardiac index	3.5 L/min/m ²	0.7
Stroke index	46 mL/beat/m ²	8.1
Total systemic resistance	1130 dynes-sec-cm ⁻⁵	178
Total pulmonary resistance	205 dynes-sec-cm ⁻⁵	51
Pulmonary arteriolar	67 dynes-	23

eTOC 在校生徒が eTOC のレッスンを
 以外の目的で使用することは法律で罰せられます。
 This document is protected by copyright.
 if you copy or distribute this file.
 English Teachers On Call

resistance

sec-cm⁻⁵

*Varies with body mass index.

SD = standard deviation.

Adapted from Barratt-Boyes BG, Wood EH: Cardiac output and related measurements and pressure values in the right heart and associated vessels, together with an analysis of the hemodynamic response to the inhalation of high oxygen mixtures in healthy subjects. *Journal of Laboratory and Clinical Medicine* 51:72–90, 1958.

Endomyocardial biopsy: This procedure helps assess transplant rejection and myocardial disorders due to infection or **infiltrative diseases**. The biopsy catheter (**bioptome**) can be passed into either ventricle, usually the right. Three to 5 samples of myocardial tissue are removed from the **septal endocardium**. The main complication, **cardiac perforation**, occurs in 0.3 to 0.5% of patients; it may cause **hemopericardium** leading to cardiac tamponade.

Coronary artery flow measurements: Coronary angiography shows the presence and degree of stenosis but not the functional significance of the lesion (ie, how much blood flows across the stenosis). Extremely thin guidewires are available with pressure sensors or Doppler flow sensors. Data from these sensors can be used to estimate blood flow, which is expressed as fractional flow reserve (FFR). FFR is the ratio of maximal flow through the stenotic area to normal maximal flow; an FFR of < 0.75 to 0.8 is considered abnormal. These flow estimates correlate well with the need for intervention and long-term outcome; lesions with good FFR do not seem to benefit from stenting. These flow measurements are most useful with intermediate lesions (40 to 70% stenosis) and with multiple lesions (to identify those that are clinically most significant).

Contraindications

Relative contraindications to cardiac catheterization include

- Renal insufficiency
- **Coagulopathy**

- Fever
- Systemic infection
- Uncontrolled arrhythmia or hypertension
- Uncompensated heart failure
- Radiopaque dye allergies in patients who have not been appropriately premedicated

Complications

Injection of radiopaque dye produces a transient sense of warmth throughout the body in many patients. Tachycardia, a slight fall in systemic pressure, an increase in CO, nausea, vomiting, and coughing may occur. Serious complications (eg, cardiac arrest, **anaphylactic** reactions, shock, seizures, **cyanosis**, renal toxicity) are rare. Rarely, **bradycardia** occurs when a large amount of dye is injected; asking the patient to cough often restores normal rhythm. Patients with a high Hct are **susceptible** to thrombosis; the Hct should be < 65% before angiography is done. Allergic reactions may include **urticaria** and **conjunctivitis**, which usually respond to diphenhydramine 50 mg IV. Bronchospasm, laryngeal edema, and dyspnea are rare reactions; they are treated with inhaled albuterol or epinephrine 0.3 to 0.4 mL sc. Anaphylactic shock is treated with epinephrine and other supportive measures. If the catheter tip contacts the ventricular endocardium, ventricular arrhythmias commonly occur, but ventricular fibrillation is rare. If it occurs, direct current (DC) cardioversion is administered immediately. Radiopaque dyes, all hypertonic, are excreted by the kidneys and may worsen renal insufficiency. For patients at risk, infusion of normal saline IV reduces this risk.

Mortality rate is 0.1 to 0.2%. MI (0.1%) and stroke (0.1%) may result in significant **morbidity**. Incidence of stroke is higher in patients > 80 yr. Dissection of a coronary artery can complicate angiography. Local vascular injury at the peripheral insertion site of catheterization can cause hemorrhage or formation of **pseudoaneurysms** or **arteriovenous fistulas**.

Reference: <http://www.merckmanuals.com>